


Case Report

Sinonasal Inverted Papilloma: A Case Report from Mali

**Mohamed Saydi Ag Mohamed Elmehdi Elansari¹, Mariam Sangare^{2,*},
Moussa Bourama Keita⁴, Lassine Dienta³, Lassana Keita², Kadidiatou Traore⁴,
Mamadou Ouattara², Diaff éDram é², Kalifa Coulibaly⁴, Nagnouma Camara⁵,
Mamadou Diallo¹, Boubacary Guindo⁴, Fatogoma Issa Kon é⁴ , Kadidiatou Singar é⁴,
Siaka Soumaoro⁴, Mohamed Amadou Keita⁴**

¹Ear, Nose and Throat (ENT) Department, Commune VI Referral Health Center, Bamako, Mali

²Ear, Nose and Throat (ENT) Department, Commune II Referral Health Center, Bamako, Mali

³Ear, Nose and Throat (ENT) Department, Hospital Somin éDolo, Mopti, Mali

⁴Ear, Nose and Throat (ENT) Department, University Hospital Gabriel Tour é Bamako, Mali

⁵Ear, Nose and Throat (ENT) Department, Commune III Referral Health Center, Bamako, Mali

Abstract

Inverted papilloma (IP) or also called Schneiderian Papilloma is an unusual and rare type of nasal tumor. Generally benign, but can have osteolytic powers and the possibility of transformation into malignancy during its evolution. Several hypotheses emerge in the literature, however the most frequent remains viral origin with the involvement of human papillomavirus (HPV). This is a case of bilateral inverted papilloma in a 60-year-old male patient at the Reference Health Center of the VI commune of the Bamako-Mali district. The symptoms appeared about 14 months ago, marked by a bilateral anterior rhinorrhea, of gradual appearance, associated with nasal obstruction, epistaxis, headaches and anosmia. Thus the diagnosis was made using physical examination and additional examinations such as the scanner of the facial massif, the anatomopathological examination of the operating room, and the test of the human papillomavirus, which turned out to be positive for HPV16 and HPV18. The management consisted of endonasal surgery, with the complete macroscopic removal of the mass and an average meatotomy accompanied by two years of follow-up after the surgical procedure. Since the PI is an aggressive tumor, its management must require long-term surveillance due to the possibility of recidivism and malignant degeneration finally to act early for these eventualities.

Keywords

Inverted Papilloma, Clinical Case, ENT Department, Bamako-Mali

1. Introduction

Inverted papilloma (IP) is an unusual type of benign tumor, accounting for 0.5–4% of nasosinus tumors, 99% of which are

unilateral [1-3]. It progresses slowly, marked by recurrence, bone lysis and transformation to malignancy [4, 5].

*Corresponding author: sangaremariam1008@gmail.com (Mariam Sangare)

Received: 29 February 2024; **Accepted:** 26 March 2024; **Published:** 11 April 2024



Copyright: © The Author(s), 2023. Published by Science Publishing Group. This is an **Open Access** article, distributed under the terms of the Creative Commons Attribution 4.0 License (<http://creativecommons.org/licenses/by/4.0/>), which permits unrestricted use, distribution and reproduction in any medium, provided the original work is properly cited.

IP was first described by Ward in 1854. In 1991, it was classified by the World Health Organization into three distinct histopathological subtypes: exophytic, inverted and oncocyctic [6]. The etiopathogenesis is not yet well elucidated, but the viral hypothesis is currently the most widely accepted, as cited by [6, 7]. The first two types are the most frequent, and the transformation to malignancy of Schneider's papilloma varies from 2 to 27 [6].

Endoscopy, CT and magnetic resonance imaging (MRI) are capitalized on in the hypothesis for determining tumor location and extension in the preliminaries before surgical intervention [8].

Although rare, IP is reported worldwide. In Mali, it has been reported at 3.33% in studies of tumors of the head and neck sphere, with no particular emphasis on management [9].

Thus, we present a case of bilateral sinonasal papilloma in the ear, nose and throat (ENT) department, in the reference health center in commune VI, Bamako-Mali.

2. Observation

This is a 60-year-old male patient with an unknown medical and surgical history. The reason for consultation was bilateral nasal obstruction, the onset of symptoms dating back some 14 months, marked by bilateral anterior rhinorrhea, of progressive onset and permanent evolution, associated with nasal obstruction, epistaxis, headache, and anosmia, without ophthalmic signs.

Physical examination:

Anterior rhinoscopy reveals a friable tissue formation filling the anterior 2/3 of both nasal cavities, bleeding on contact and associated with serous rhinorrhea.

Examination of the oral cavity and oropharynx revealed poor oral hygiene.

Other ENT examinations were unremarkable.

The patient was followed up for two years and tested positive for Human Papilloma Virus (HPV 16 and 18).

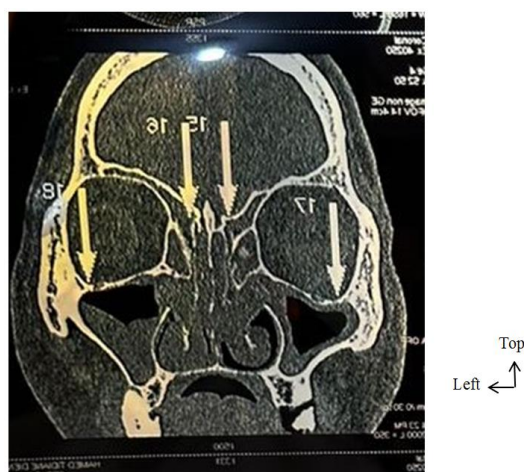


Figure 1. CT scan of the facial mass: axial section.

A CT scan of the facial mass revealed tissue hypodensity, with partial filling of both nasal cavities and the left maxillary sinus, and complete filling of the right maxillary, ethmoid and frontal sinuses, with contrast enhancement after injection. Lysis of the anterior walls of the maxillary and ethmoid sinuses.

Anatomopathological examination revealed an endonasal inverted papilloma.

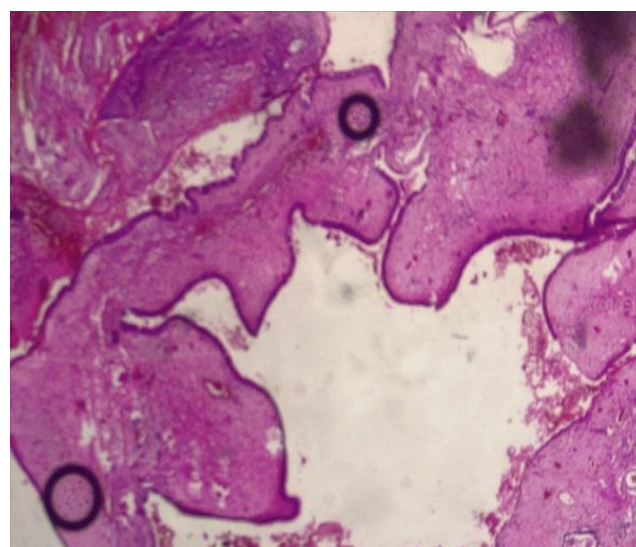


Figure 2. Anatomical pathology examination.

The patient underwent endonasal surgery, with complete macroscopic removal of the mass, medium meatotomy.

3. Discussion

Naso-sinusal inverted papilloma is a generally rare tumor in terms of the number of confirmed cases [8]. Its incidence ranging from 0.4% to 4.7% of all sinonasal tumors [2, 5, 7, 10]. In Mali, Keita et al. found an incidence of 3.33% of cases out of 60 colligated tumors of the head and neck sphere collected in one year [9].

We present the case of a 60-year-old male patient. In Congo Sangol et al. also report a male case aged 40 [8]. Boujguenna et al. [11], found 73% males out of 15 cases with extreme ages ranging from 11 to 70. According to the literature, PI occurs exceptionally in children, and affects men more than women, with a predilection for ages between 50 and 70 [5, 8]. This male predominance is four to five times greater than that of the female [1], and remains an unexplained situation. On the other hand, in Côte d'Ivoire, N'gatie et al. [12], found six (6) female cases, aged between 8 and 57.

In our case, the consultation time was 14 months. The authors also report a consultation delay varying from 12 to 66 months [13, 14]. This could be explained by the slow evolution of IP and the difficulty of access to care in our country.

The same idea was supported by Sangol et al. [8].

Clinically, the symptomatology of our case agrees with that of authors who report the presence of rhinorrhea, nasal obstruction, epistaxis, etc.... [5, 15]. This was a bilateral case, which is rare in the literature, where 99% of reported cases are bilateral [1]. However, we did not find any medical, surgical or environmental antecedents in our case, unlike Sangol et al. [8], who found smoking for over 13 years with a consumption of 7.8 packs per year as an environmental antecedent. As for Sunkara et al. [2], occupational factors and industrial exposures favor the appearance of IP, and smoking contributes to its transformation into a malignant tumor. According to the literature, its etio-pathogenesis remains poorly elucidated [8] particularly that of HPV, but there is conflicting evidence as to its role [2]. Syrjanien [16], reports that 33% of IP are associated with HPV. We agree that our patient was HPV-positive. The benign or malignant prognosis depends on the HPV type. HPV-6 and 11 are considered low-risk types, while HPV-16 and 18 are considered high-risk [3]. In addition to the HPV subtype implicated in the occurrence of IP, Salomone et al. [1] adds "inflammatory origin and/or chronic infectious rhinosinusitis, exposure to toxic substances, allergic processes, Epstein-Barr virus."

In terms of paraclinical data, CT scans of the facial mass showed lysis of the anterior walls of the maxillary and ethmoid sinuses, and histological examination of the surgical specimen confirmed the diagnosis. The latter was the only additional examination also used in the case study by Sangol et al. [8] to confirm the diagnosis of IP. However, our patient did not undergo an MRI, due to the difficulty of access to this examination in our country. CT scan combined with an MRI can identify signs of malignancy (bone lysis), the presence of a necrotic component, delineate tumor extension and subsequently guide therapeutic decisions [7, 16]. In the case reported by Solomone et al [1], nasofibroscopy was performed to assess the condition of the nasal cavities and the macroscopic nature of the tumor.

We performed endonasal surgery, with complete macroscopic removal of the mass and a middle meatotomy. In contrast, in the Congo, Sangol and al. [8] report that, due to a lack of endoscopes, external approach surgery was most frequently used in the university clinics of Lubumbashi. The approach can be external or endonasal under endoscopic guidance, depending on the location of the tumor and the surgeon's experience. However, the endoscopically guided endonasal approach is the new technique adopted since the 1990s, and is the most widely recommended and practiced [17]. Alami et al. [7], report that in stage T4 squamous cell carcinomas resulting from inverted papilloma, radical surgical resection combined with postoperative adjuvant therapy, as well as chemotherapy and radiotherapy, can be effective in the management of the latter.

Our patient was followed for 2 years. Salomone et al. [1] underwent postoperative monitoring every two months for the first six months by nasal endoscopy, which showed a re-epithelialized nasal cavity with no evidence of disease

recurrence. The authors also performed a two-year follow-up after complete excision of the mass [8]. According to Long et al. [3], the incidence of malignancy is between 5 and 10%, and recurrence and malignant transformation may occur more than 8 years later, hence the need for long-term post-operative follow-up.

4. Conclusion

Sinonasal Inverted Papilloma is an aggressive, benign tumor of unknown etiology. Endoscopic surgery is the technique of choice for its management, but it has its limitations. Consequently, its management requires long-term post-operative follow-up due to the possibility of recurrence and malignant degeneration.

Abbreviations

ENT: Ear Nose and Throat

HPV: Human Papilloma Virus

IP: Inverted Papilloma

MRI: Magnetic Resonance Imaging

Conflicts of Interest

The authors declare no conflicts of interest.

References

- [1] Salomone R, Matsuyama C, Giannotti Filho O, Alvarenga ML, Martinez Neto EE, Chaves AG. Bilateral inverted papilloma: case report and literature review. *Braz J Otorhinolaryngol*. 2008 Mar-Apr; 74(2): 293-6. [https://doi.org/10.1016/s1808-8694\(15\)31103-4](https://doi.org/10.1016/s1808-8694(15)31103-4)
- [2] Sunkara PR, Saraswathula A, Ramanathan M Jr. Etiology of sinonasal inverted papilloma: An update. *Laryngoscope Investig Otolaryngol*. 2022 Aug 24; 7(5): 1265-1273. <https://doi.org/10.1002/lio2.821>
- [3] Long C, Jabarin B, Harvey A, et al. Clinical evidence based review and systematic scientific review in the identification of malignant transformation of inverted papilloma. *J of Otolaryngol - Head & Neck Surg*. 2020; 49(25). <https://doi.org/10.1186/s40463-020-00420-x>
- [4] Bonfils P. Benign tumors of the nose and sinuses. *Nasosinusal inverted papilloma*. *EMC-Otolaryngologie* 2007; 20: 400-410.
- [5] Bououzrou O. Inverted nasosinusal papillomas: Experience of the HMA's ENT service. [Medicine Thesis]. Faculty of Medicine and Pharmacy - Marrakech; 2022.
- [6] Nudell J, Chiosea S, Thompson LDR. Carcinoma Ex-Schneiderian Papilloma (Malignant Transformation): A Clinicopathologic and Immunophenotypic Study of 20 Cases Combined with a Comprehensive Review of the Literature. *Head Neck Pathol*. 2014; 8(3): 269-286.

- [7] Alami Z, ZahraeFarhane F, Amrani S, Hassani W, Bouhafa T. Squamous cell carcinoma on inverted papilloma of the maxillary sinus: About a case. *IJAR*. 2021; 9(11): 739-41. <https://doi.org/10.21474/IJAR01/13798>
- [8] Sangol H, M., Kyungu Agnès, M., Fatuma, M., Luty, N., Kalungwe, K., Sandra, Y. M., Marie Jeanne, K. I., & Borasisi, C. Papilloma Inverse Nasosinusien: À Propos D'un CAS Aux Cliniques Universitaires De Lubumbashi /RDC. *International Journal of Medical Science and Clinical Invention*. 2022; 9(10): 6296-6298. <https://doi.org/10.18535/ijmsci/v9i10.05>
- [9] Keita M, Kampo M I, Timbo SK, Traoré CB, Diallo M, Doumbia-Singaré K., Ag Mohamed A. Morbidity of the tumours of the sphere head and neck in Bamako. *Mali Medical*. 2009; Tome XXIV (3): P. 6.
- [10] Lawson W, Ho BT, Shaari CM, Biller hf. Inverted papilloma: à report of 112 cases. *Laryngoscope* 1995; 105: 228-88.
- [11] Boujguenna I, Elhatimy S, Mansouri N, Rochdi Y, Nouri H, Raji A, Bouyaali CH., Cherif Gannoun Idrissi N, Fakhri A and Rais H. Sinonasal Inverted Papilloma: Epidemiological and Pathological Profile from 15 Cases. *Toxi App Phar Insig*. 2020; 3(1): 16-9.
- [12] N'Gattia KV, Kacouchia NB, Mobio NM, Kouassi YM, Vroh BT, Yoda M, Kouassi-Ndjeundo J, Buraima F, Tanon-Anoht MJ, Kouassi. Sinonasal inverted papilloma: our experiences of diagnostic and surgical care in Côte d'Ivoire. *Rev Med Brux*. 2014 Jan-Feb; 35(1): 4-9. French. PMID: 24683835.
- [13] Lawson W, Schlecht NF, Brandwein-Gensler M. The role of the humanpapillo-mavirus in the pathogenesis of Schneiderian inverted papillomas: an analyticoverview of the evidence. *Head Neck Pathol*. 2008 Jun; 2(2): 49-59. PubMed| Google Scholar.
- [14] Pasquini E, Sciarretta V, Farneti G, Modugno GC, Ceroni AR. Inverted papilloma: report of 89 cases. *Am J Otolaryngol*. 2004; 25(3): 178-85. PubMed| Google Scholar.
- [15] Amouzoune S, Ammar H. Inverted papilloma: retrospective study proposing 18 cases in the ENT department of the Avi-cenne Marrakech Military Hospital. [Medicine Thesis]. Mar-rakech. 2013. Google Scholar.
- [16] Syrjanen KJ. HPV infections in benign and malignant sinonasal lesions. *J Clin Pathol* 2003; 56: 174-81.
- [17] Eggers G, Mühling J, Hassfeld S. Invertedpapilloma of paranasalsinuses. *J Cranio maxillo fac Surg*. 2007; 35(1): 21-9. PubMed| Google Scholar.