

A Rare Case of Post-Traumatic Open Laryngeal Fracture

Rajkumari P. Khatri

ENT & Head and Neck Oncology Center, Indore, India

Email address:

raj.sachdeva@rediffmail.com

To cite this article:

Rajkumari P. Khatri. (2023). A Rare Case of Post-Traumatic Open Laryngeal Fracture. *International Journal of Otorhinolaryngology*, 9(2), 35-39. <https://doi.org/10.11648/j.ijo.20230902.19>

Received: MM DD, 2023; **Accepted:** MM DD, 2023; **Published:** MM DD, 2023

Abstract: Laryngeal fracture is a rare and potentially fatal traumatic injury, with an estimated incidence of 1 in 30,000 patients admitted to severe trauma centres. This is usually seen in multiple-trauma patients and is often undiagnosed or poorly managed leading to significant problems with airway patency, voice production, and swallowing; and the overall mortality rate being as high as 17.9%. This paper reports a case of a 28-year-old male patient, whose motorcycle accidentally hit a truck. The patient presented with a lacerated open neck wound with multiple small lacerated wounds on the skin over the neck and chin. The CT scan revealed a severe burst injury of the anterior larynx with fractured thyroid laminae, and the larynx was exposed to the external surface. Method: A series of investigations followed, including assessing patient's medical records, performing medical and surgical interventions and lastly taking patient feedback. Results: Early intervention with an open reduction and internal fixation of the thyroid cartilage helped restore the near-normal anatomy of the larynx. Post-operatively, he had no problems in swallowing or breathing; except for some hoarseness of voice, which improved considerably within six months post-surgery. Conclusions: Because of the rarity of this injury, physicians may not be aware of its occurrence, leading to a late diagnosis of this entity. Early diagnosis of the laryngeal injury is indispensable. The most important goal in management initially is to secure and reconstruct the airway; thereafter, the long-term goal of treatment is to restore the voice and swallowing mechanism.

Keywords: Laryngeal Trauma, Laryngeal Fracture, Thyroid Cartilage Fracture, Cut-Throat Injury, Blunt Neck Injury

1. Introduction

The Laryngeal fracture is a rare and potentially fatal traumatic injury due to the high mobility of the larynx and the protection it receives from the surrounding bony structures of the sternum, mandible, and cervical spine. [1] An estimated incidence of between 1 in 14000 and 1 in 30,000 patients admitted to severe trauma centers accounts for less than 1% of all cases seen at major trauma centers. The overall mortality rate is 17.9% [2].

Most laryngeal fractures are of the closed type and are caused by blunt neck trauma. The open laryngeal fracture is exceptional and is seen particularly in penetrating neck traumas like gunshot injuries. Laryngeal fractures associated with open neck wounds are commonly homicidal or suicidal and rarely accidental, sustained in vehicular or industrial accidents. They are frequently left undiagnosed due to their closed nature and accompanying multisystem trauma, leading to significant problems with airway patency,

phonation, and swallowing. [2]

This paper presents, an unusual case of open laryngeal fracture following blunt neck trauma that occurred during a motorcycle accident, in which the patient was breathing comfortably from the lacerated open neck wound at the level of the thyroid cartilage as if a laryngotomy had been done.

An isolated fracture of the thyroid cartilage is the most frequent injury encountered. The incidence of laryngeal cartilage fractures ranges from 0 to 67%. Injuries involving the cricoid cartilage are rare. It has a mortality rate of as high as 40% [2]. A missed significant laryngeal injury could ultimately have serious life-threatening consequences, such as fracture, swelling, airway obstruction, and death or may cause significant long-term sequelae like dysphonia, aspiration, and airway stenosis. The ultimate goal is to secure a safe and atraumatic airway [1].

Clinical evaluation includes an endoscopic examination of the larynx using fiberoptic endoscopy, or direct laryngoscopy under general anesthesia. It can guide the clinician in securing the airway, and assessing the grading of injury, and

establishing a surgical plan [3].

Types of laryngeal fractures:

There are four types of laryngeal fractures as described below:

- 1) Supraglottic laryngeal fracture causing posterior displacement of the epiglottis and laryngeal inlet
- 2) Cricotracheal separation: usually fatal
- 3) Vertical midline fracture which will damage the anterior commissure and separate the thyroid alae
- 4) Comminuted fracture: usually common in older, calcified, and rigid larynx [3]

Classification of Schaefer-Fuhrman for laryngeal fractures is given in Table 1.

Table 1. Classification of Laryngeal Fractures.

Groups	Severity of injury in ascending order
Group 1	Minor endolaryngeal hematomas or lacerations without detectable fractures
Group 2	More severe edema, hematoma, minor mucosal disruption without exposed cartilage, or nondisplaced fractures
Group 3	Massive edema, large mucosal lacerations, exposed cartilage, displaced fractures, or vocal cord immobility.
Group 4	Same as group 3, but more severe, with disruption of anterior larynx, unstable fractures, two or more fracture lines, or severe mucosal injuries
Group 5	Complete laryngotracheal separation

Management depends on the type and severity of injury and this classification is a useful guide [2]. The present case was compatible with group IV which is defined as having disruption of the anterior larynx, unstable fractures, two or more fracture lines, or severe mucosal injuries.

1.1. Diagnosis

A CT scan of the neck is the gold standard for diagnosing this type of injury and also helps to rule out cervical spine injuries and other organ injuries due to the high probability of concurrent injuries associated with laryngeal trauma [4]. A CT scan of the neck and chest is indicated in stable patients, because it can detect occult fractures and whether or not there are displaced fractures of the cartilaginous larynx. In the case of the unstable patient the X-ray Chest is done, which may show a pneumothorax, pneumomediastinum, subcutaneous emphysema, or tracheal deviation.

1.2. Treatment / Management

Management depends on the type and severity of injury. It is widely agreed that early intervention of laryngeal injuries yields superior results, ideally within the first 24 to 48 hours [2, 5, 6, 7]. In the present case, the surgical intervention was done within 48 hours.

2. Method

This study used a case study method of investigation going through patient medical records, medical and surgical intervention, and patient feedback.

3. Case Report

A 28-year-old male patient was admitted to the emergency room after a motorcycle accident with a truck. The Patient presented with a lacerated open neck wound with multiple small lacerated lesions of the skin over the neck and chin. The Patient was breathing comfortably from a lacerated open neck wound as if a laryngostomy had been done. (See Figure 1)

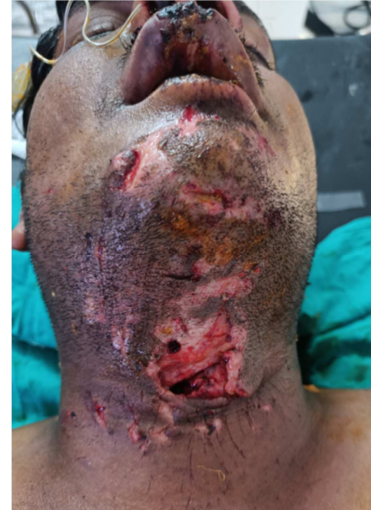

Figure 1. Cut throat injury revealing open laryngeal Fracture.

The Patient was conscious and haemo-dynamically stable, but unable to speak. On local examination, the skin and muscles of the neck were edematous, lacerated, and infected with discharge coming from the wound. A considerable amount of edema and ecchymosis of both false vocal cords and aryepiglottic folds. Both vocal cords were seen in the lower part of the fractured thyroid cartilage.

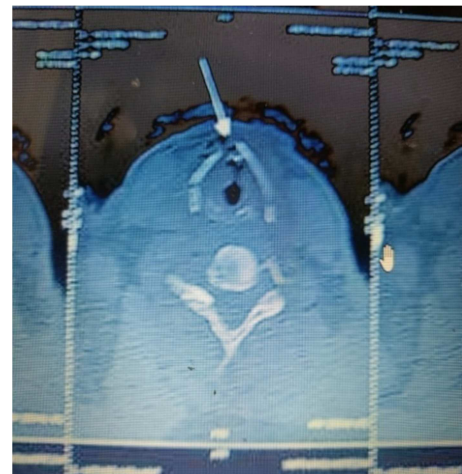


Figure 2. CT scan.

The CT scan (Figure 2) revealed a severe burst injury of the anterior larynx with an open comminuted fracture of the thyroid cartilage. After acute stabilization, the patient underwent a CT scan which revealed a burst injury of the anterior larynx and severe local subcutaneous and skin injury,

and internal laryngeal structures were swollen.

There was also an associated linear fracture of the mandible in the midline and a non-displaced thin fracture of the anterior margin of the hyoid bone. Thorough suction cleaning & toileting of the wound was done with all aseptic precautions. Intravenous antibiotics (cefotaxime, gentamicin, metrogyl) analgesic & anti-inflammatory, antireflux, and steroid drugs were started along with tetanus vaccination. Considering the Grade IV laryngeal injury as having disruption of the anterior larynx, unstable fractures, two or more fracture lines, or severe mucosal injuries, decision was taken to perform a surgical exploration via this open neck wound.

Surgery

Taken under General Anesthesia, the airway is established using an endotracheal tube inserted through the neck directly into the trachea distal to the site of transection. The surgical exploration was done via the open neck wound, Superior & inferior skin, subcutaneous & muscle flaps are elevated by blunt and sharp dissection. All necrotic soft tissue was excised, and the larynx was exposed fully. The thyroid cartilage had a horizontal fracture which divides it into upper & lower half, while the upper half is further fractured in the midline and multiple small pieces bilaterally.

- 1) All the Thyroid cartilage pieces along with the perichondrium are sutured with 2-0 prolene to bring anatomical continuity.
- 2) In the thick Calcified thyroid cartilage in the midline, holes are made for the suturing by drill.

After completion, the Direct Laryngoscopy was done which is shown in Figure 3.

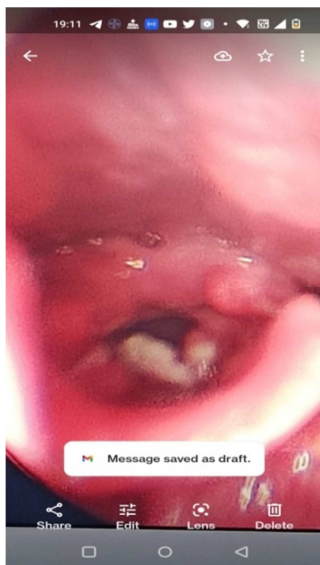

Figure 3. Post-op Direct Laryngoscopy revealed normal endolarynx except for a small mucosal tag in the supraglottis.

The post-op was uneventful, and after 48 hrs. he was extubated and shifted to the ward. Ryle's tube feeding started 24 hours after extubation. After 2 days, there was no neck swelling, the neck drain was nil and was removed. He was discharged on the 7th day.

Thus, early intervention with an open reduction and internal fixation of the thyroid cartilage helped to restore the near-normal anatomy of the larynx and the functional outcomes in terms of respiration, swallowing, and phonation without any sequelae.

Approximately 4 weeks after injury, direct tele laryngoscopy was done, both vocal cords were mobile, the voice was clear but mild hoarseness was there and oral intake started. After 6 months the voice was almost normal, as assessed by a telephonic communication with the patient.

4. Discussion

This study was conducted with the following aims and objectives:

- 1) Understand the etiology of laryngeal trauma/fracture.
- 2) Summarize clinical presentation & endoscopic findings of laryngeal trauma/fracture.
- 3) Management of laryngeal injury, and its outcome.
- 4) Monitoring patient for airway compromise or restoration of functions of the larynx in the longer term to reduce complications.

Laryngeal fracture is an infrequent injury, High speed motor vehicle accidents were the most common mechanism (49%), followed by sports-related injuries (29%) [1, 6]. Other causes are strangulation, and hanging. Penetrating trauma is the second leading cause, often due to assault by gunshot or stab wounds to the neck [1]. But, nowadays owing to industrialization and urbanization penetrating trauma is also on the increase because of machine-related accidents and stabbings [5]. Laryngeal trauma has a high mortality rate (17.9% to 40%), because of severe airway injury or multiple organ injury [1, 8]. An injured airway may be missed initially as symptoms on admission do not always correlate with the degree of internal injury. The recommendation is to perform CT within 24 hours of trauma [4, 6].

4.1. Airway Management

Airway management in these patients with laryngeal trauma is the main priority [5, 7]. Both endotracheal intubation and tracheotomy have been recommended. The ultimate goal is to secure a safe and atraumatic airway, and restore the normal anatomy of the larynx to improve the long-term voice outcome, and swallowing in these patients [9].

Mendelsohn et al. recommended a tracheostomy within 24 hours to secure the airway [10]. Butler et al. found that early treatment within 48 hours resulted in significantly better outcomes for voice and airway function when compared to delayed treatment [1, 2, 8, 11]. as even a minimal displacement of fractures can disrupt normal phonation [12].

A CT scan of the neck is considered to be the gold standard for diagnosing such injuries. Indeed, Duda Jr. et al. report that by its superior contrast resolution, MR imaging may be preferable in detecting epiglottic injuries, including avulsion [5, 7, 9, 13].

Patients with respiratory distress or increasing stridor

should be intubated immediately. However, the most appropriate method for airway management is controversial. Intubating a patient who has sustained laryngeal trauma can be extremely difficult because of distorted anatomy, poor visualization, and suboptimal conditions. Additionally, trans-oral intubation may lead to catastrophic results like worsening the preexisting injury, creating false passages, causing further trauma to an injured larynx, disrupting damaged mucosa, and cricotracheal separation, and potentially compromising the stability of the patient [10].

However, in the present case, the presentation was very exceptional. At the admission, the patient was breathing comfortably from a lacerated open wound at the level of the thyroid cartilage as if a laryngectomy had been done (Figure 1). There was no respiratory distress, and the airway was secured but not safe.

About 37% of the patients in the reported series had delayed diagnosis hence the need for a high level of suspicion of any anterior cervical trauma [14].

Open fractures of the laryngeal framework are quite uncommon for a blunt neck injury. On the contrary, fractures of the larynx are more likely to be "open" internally, where the defect may be through the mucosa rather than the skin, and therefore missed by external examination alone. These injuries may ultimately require endoscopic or open repair, or tracheotomy [2].

A complete trauma assessment must be performed to rule out associated injuries like skull base or intracranial injury (13%), open neck injury (9%), cervical spine injury (8%), and oesophageal or pharyngeal injury (3%) [2]. There is also a high incidence of associated recurrent laryngeal nerve injury in patients with the fracture of the cricoid cartilage because of the proximity to the nerve. Injury to major vessels and the thyroid gland are also commonly seen. A CT angiogram may also be indicated if there is suspicion of concomitant vascular injury. MRI currently has no role in the evaluation of laryngotracheal injury [14].

In the present case, there was an associated linear non-displaced fracture of the hyoid bone, no intervention was done and the midline mandibular fracture was reduced by ORIF by nailing and plating by fascio-maxillary surgeon.

The external perichondrium of the cartilage should always be re-approximated. Mucosal defects are repaired with absorbable sutures and buried knots to prevent granuloma formation. If there is extensive mucosal loss, free grafts from the buccal mucosa, skin, or dermis may be used to fix the defect [5]. When laryngeal fractures occur, stenosis and deformity may occur in the airway and vocal tract unless proper repair is undertaken. [5, 8]. An interesting rabbit study by Dray et al. found cartilaginous healing of fractures fixed with plates, but fibrous healing in those fixed with wire [15]. Endolaryngeal stenting is reserved for severe laryngeal trauma, comminuted fractures, and where the anterior commissure is significantly disrupted [1].

In the present case, the glottis was intact, and only the supraglottic part was fractured, so after open reduction and fixation of fractured fragments. The patient was kept

intubated for only 48 hours till the edema subsided.

4.2. Postoperative and Rehabilitation Care

Antibiotics, steroids, antihistamines, and antireflux medications should be considered.

In literature 62 to 85% of cases, there is a good voice outcome, with good airway outcomes achieved in 76 to 97% of cases. The better outcome occurred in people who were treated early compared to those who received delayed treatment [16]. Age has a direct influence on prognosis as an older patient tends to have poor outcomes, especially if over 70 years of age [17].

The complications usually encountered are:

Acute:

- 1) upper airway obstruction and asphyxia
- 2) bleeding, hematoma infection
- 3) fistula formation
- 4) Loss of airway
- 5) Recurrent laryngeal nerve injury
- 6) death.

Chronic:

- 1) Vocal cord paralysis
- 2) Hoarseness
- 3) Recurrent granulation formation
- 4) airway stenosis,
- 5) Recurrent laryngeal nerve dysfunction
- 6) chronic aspiration
- 7) Reduction in voice quality [18, 19].

5. Conclusion

The key step in the treatment of any laryngeal injury is the establishment of a secure airway and reconstruction of the airway. Early diagnosis & intervention (within 24–48 hours) of the laryngeal injury is indispensable, as it not only protects the airway but also improves long-term patient outcomes. Significant long-term sequelae like dysphonia, aspiration, airway stenosis, and pharyngeal fistula may occur if intervention is delayed. Open comminuted laryngeal fracture is rare. A high index of suspicion is needed for early diagnosis in cases of anterior neck injury. The emergency physician should avoid trans-oral intubation, as it may lead to irremediable results, especially in comminuted fractures or arytenoid dislocation. For displaced thyroid fracture ORIF is recommended.

Ethical Approval

Not required.

Acknowledgments

The author would like to give thanks to Laxmi Memorial Hospital, Indore for allowing the operation on this rare case, to the administration for providing me with the records for the documentation, and to the patient for his cooperation in sharing the case data and feedback on condition of

anonymity. Special thanks to Dr. V. S. Nanduri for providing support in writing this article.

Conflicts of Interest

All the authors do not have any possible conflicts of interest.

References

- [1] Hicham Attif, Ayman Elfarouki, Karim Nadour, Mounir Hmidi, Nabil Touihem, Ali Elboukhari, Brahim Zainoun. Diagnosis and management of laryngeal fracture: a case report. *International Journal of Otorhinolaryngology and Head and Neck Surgery*. 2017; 3 (4): 1095-1098.
- [2] G. S. Gussack, G. J. Jurkovich, and A. Luterman, "Laryngotracheal trauma: a protocol approach to a rare injury," *Laryngoscope*, vol. 96, no. 6, pp. 660-665, 1986. View at: Google Scholar.
- [3] Statpearls.com, Laryngeal Fracture Article. Available from: <https://www.statpearls.com/Article/library/viewarticle/24038#ref-7114721>.
- [4] S. D. Schaefer, "The acute management of external laryngeal trauma. A 27-year experience," *Archives of Otolaryngology—Head and Neck Surgery*, vol. 118, no. 6, pp. 598-604, 1992. View at: Publisher Site | Google Scholar.
- [5] Philicia Moonsamy, Uma M. Sachdeva, Christopher R. Morse. Management of laryngotracheal trauma. *Ann Cardiothorac Surg* 2018; 7 (2): 210-216.
- [6] Nadir Elias, James Thomas, Allen Cheng. Management of Laryngeal Trauma. *Oral Maxillofac Surg*. 2006; 64 (2): 203-14.
- [7] Nuno Ribeiro-Costa, Pedro Carneiro Sousa, Diogo Abreu Pereira, Paula Azevedo, and Delfim Duarte. Laryngeal Fracture after Blunt Cervical Trauma in Motorcycle Accident and Its Management Case Reports in Otolaryngology Volume 2017, Article ID 9321975, 3 pages <https://doi.org/10.1155/2017/9321975>
- [8] Bassel Hallak, Sonia Von Wihl, Franciscus Boselie, Salim Bouayed. Repair of displaced thyroid cartilage fracture using miniplate osteosynthesis. *BMJ Case Rep* 2018; 11: e226677. doi: 10.1136/bcr-2018-226677.
- [9] Nathan Schaefer, Aaron Griffin, Benjamin Gerhardy, Peter Gochee. Early Recognition and Management of Laryngeal Fracture: A Case Report. *The Ochsner Journal* 2014; 14: 264-265.
- [10] Mendelsohn AH, Sidell DR, Berke GS, John MS. Optimal timing of surgical intervention following adult laryngeal trauma. *Laryngoscope*. 2011 Oct; 121 (10): 2122-2127. Epub 2011 Sep 6.
- [11] Butler AP, Wood BP, O'Rourke AK, Porubsky ES. Acute external laryngeal trauma: experience with 112 patients. *Ann OtolRhinolLaryngol*. 2005 May; 114 (5): 361-368.
- [12] Pou AM, Shoemaker DL, Carrau RL, Snyderman CH, Eibling DE. Repair of laryngeal fractures using adaptation plates. *Head & neck*. 1998 Dec; 20 (8): 707-13 [PubMed PMID: 9790292].
- [13] Duda JJ Jr, Lewin JS, Eliachar I. MR evaluation of epiglottic disruption. *AJNR Am J Neuroradiol*. 1996 Mar; 17 (3): 563-6. PMID: 8881254; PMCID: PMC8338005.
- [14] Burak Ulkumen, Onur Celik, Nevin Sahin. Open Laryngeal Fracture: A case report and review of the literature. *Medical Science and Discovery*. 2015; 2 (5): 304-07.
- [15] Dray TG, Coltrera MD, Pinczower EF. Thyroid cartilage fracture repair in rabbits: comparing healing with wire and miniplate fixation. *Laryngoscope* 1999; 109: 118-22.
- [16] Kuttenger JJ, Hardt N, Schlegel C. Diagnosis and initial management of laryngotracheal injuries associated with facial fractures. *Journal of cranio-maxillo-facial surgery: Official publication of the European Association for Cranio-maxillo-facial Surgery*. 2004 Apr; 32 (2): 80-4 [PubMed PMID: 14980586].
- [17] AJewett BS, Shockley WW, Rutledge R. External laryngeal trauma analysis of 392 patients. *Archives of otolaryngology--head & neck surgery*. 1999 Aug; 125 (8): 877-80 [PubMed PMID: 10448735].
- [18] Jalisi S, Zoccoli M. Management of laryngeal fractures--a 10-year experience. *Journal of Voice: Official journal of the Voice Foundation*. 2011 Jul; 25 (4): 473-9. doi: 10.1016/j.jvoice.2009.12.008. Epub 2010 Mar 17 [PubMed PMID: 20236793].
- [19] Kurien M, Zachariah N. External laryngotracheal trauma in children. *International journal of pediatric otorhinolaryngology*. 1999 Aug 5; 49 (2): 115-9 [PubMed PMID: 10504017].